

(SD2021-212) A tool to assess and monitor wound health -

Tech ID: 32597 / UC Case 2021-Z08-1

ABSTRACT

Researchers from UC San Diego have developed a patent-pending device that solves all these major limitations. It is a quick, inexpensive, non-radiative, non-invasive, point-of-care imaging modality. The inventors created a fast, point-of-care imaging technique that can image deep within soft tissues. This technique can be used to monitor wound health over long periods of time. This ultrasound imaging technology is poised to become a medical imaging tool to measure, and visualize wound size, progression, tunneling, and skin graft integration or rejection.

TECHNOLOGY DESCRIPTION

Background. Existing wound care practices use visual cues that are largely superficial in nature. The visual nature of the exams makes them very subjective and there is extensive inhomogeneity in wound evaluations between different healthcare professionals. Imaging is an indispensable tool to see what the eye cannot. Current techniques are limited to image a few millimeters deep into wounded tissue, thus visual examination is limited to the skin surface whereas wounds can exacerbate from deep within soft tissues.

Researchers from UC San Diego have developed a device that solves all these major limitations. It is a quick, inexpensive, non-radiative, non-invasive, point-of-care imaging modality. The inventors created a fast, point-of-care imaging technique that can image deep within soft tissues. This technique can be used to monitor wound health over long periods of time. This ultrasound imaging technology is poised to become a medical imaging tool to measure, and visualize wound size, progression, tunneling, and skin graft integration or rejection.

The patent application (PCT) is available online: <https://patents.google.com/patent/WO2022155416A1/en?q=WO+2022%2f155416>

CONTACT

Skip Cynar
scynar@ucsd.edu
tel: 858-822-2672.



OTHER INFORMATION

KEYWORDS

Tissue regeneration and wound sizing, Skin grafts, Point of care ultrasound imaging, Chronic wound care, wound healing, wound prediction, optoacoustic imaging, neovascularization, angiogenesis, healing time, early diagnosis

CATEGORIZED AS

- ▶ **Imaging**
 - ▶ Medical
- ▶ **Medical**
 - ▶ Diagnostics
 - ▶ Disease: Dermatology

RELATED CASES

2021-Z08-1

(54) Title: POINT OF CARE ULTRASOUND AS A TOOL TO ASSESS WOUND SIZE AND TISSUE REGENERATION AFTER SKIN GRAFTING

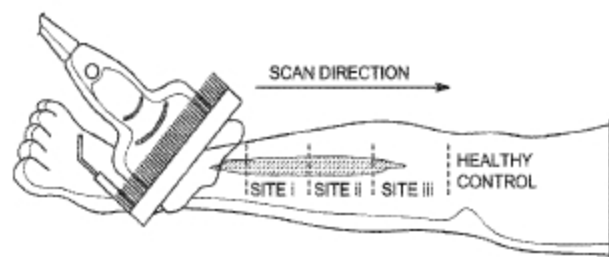


FIG. 1A

(57) Abstract: A method is provided for treating a skin wound. In accordance with the method, an ultrasound image is obtained of a skin wound on a patient. The ultrasound image is processed to extract information that is correlated to a degree of wound healing. The degree of wound healing is assessed based at least in part on the extracted information. The skin wound is treated based at least in part based on the assessed degree of wound healing.

APPLICATIONS

ADVANTAGES

Conventional wound care practices use visual cues to assess and monitor wound health.

Ultrasound imaging is a valuable tool to study skin graft integration used for chronic wound treatment. ultrasound imaging is a remarkable tool to monitor wound size, skin graft integration, soft tissue loss, and regeneration both before and after skin grafting.

STATE OF DEVELOPMENT

Photoacoustic imaging is similar to ultrasound but uses light as an excitation source to produce pressure waves. It has already shown promise in visualizing ulcers and neovascularization in mice, which is key for wound healing and skin graft integration. Our future work will look to incorporate photoacoustic imaging to monitor neovascularization in human subjects.

Figure from Mantri et al 2022 citation (below):

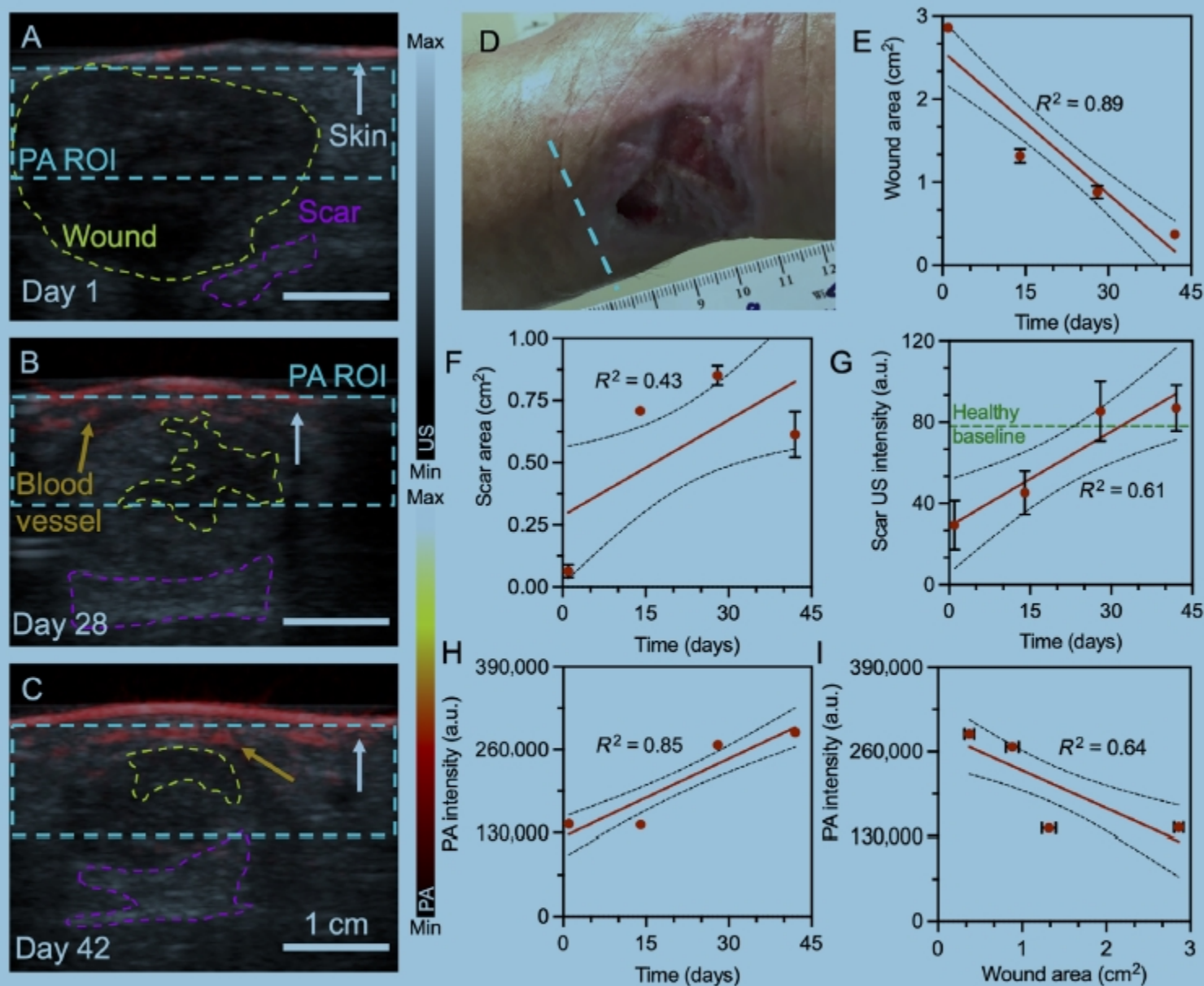


FIGURE 2 Tunelling wounds; wound closure, scar tissue development and angiogenesis. (A–C) US-PA overlay of the wound on days 1, 28 and 42 of the study. Yellow, purple and blue dotted lines in A–C represent wound, scar area and PA ROI, respectively. White and orange arrows represent skin surface and blood vessels, respectively. (D) Photographic image of wound in the left posterior ankle region. There is significant tunnelling of the wound (not seen by eye). Blue dotted line in D indicates the relative imaging plane for panels A–C. (E) 87% wound contraction is seen within 42-days. (F,G) Scar tissue development is seen as hyperechoic regions at the wound bed. (H) Significant increase in PA intensity over time indicates angiogenesis. (I) A negative correlation between PA intensity and wound area suggests angiogenesis results in wound closure. Scale bars represent 1 cm. Error bars represent standard deviation in three frames at the centre of the wound. Error bars for PA intensity in H and I are too small to be shown

INTELLECTUAL PROPERTY INFO

UC San Diego is protecting patent rights and is looking for companies interested in commercializing this technology. US patent rights are available for licensing.

RELATED MATERIALS

- ▶ Mantri, Yash, et al. "Photoacoustic Monitoring of Angiogenesis Predicts Response to Therapy in Healing Wounds." *Wound Repair and Regeneration*, vol. 30, no. 2, 2022, pp. 258–67, <https://doi.org/10.1111/wrr.12992>. - 01/12/2022
- ▶ Mantri Y, Tsujimoto J, Penny WF, Garimella PS, Anderson CA, Jokerst JV. Point-of-Care Ultrasound as a Tool to Assess Wound Size and Tissue Regeneration after Skin Grafting. *Ultrasound Med Biol*. 2021 Sep;47(9):2550-2559. - 07/29/2021

