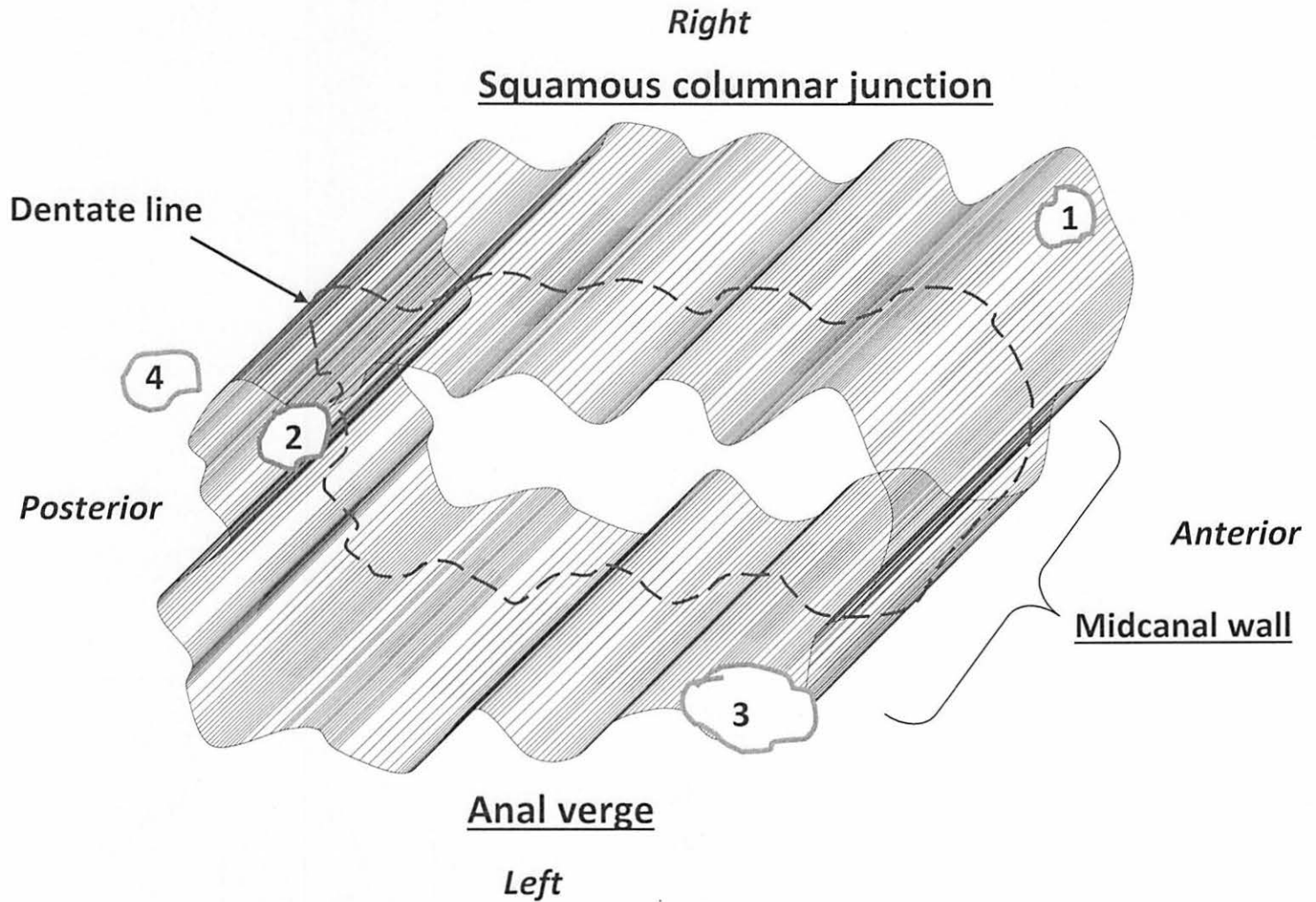


High resolution anoscopy schematic findings



‘Based on patient lying on left lateral position and with respect patient’s anatomical landmarks ‘

Lesion #1: squamocolumnar junction, right anterior, acetowhitening and punctuation, lugol negative

Lesion #2: midwall canal, right posterior, coarse punctuation

Lesion #3: anal verge, left anterior, large condyloma-like lesion

Lesion #4: Satellite lesion in anal verge, right posterior, ulceration with irregular borders